

Clinical characteristics, diagnosis and surgical management of hydatid cysts

Saeed Ali Abu-Eshy

Department of Surgery, College of Medicine,
King Khalid University, Abha, Saudi Arabia

[E-mail: saeed@kku.edu.sa](mailto:saeed@kku.edu.sa)

Summary

Echinococcosis was described by Hippocrates more than two thousand years as a "fluid-filled liver"; followed by the famous Arabian physician "Al-Rahzes." It is endemic in the Middle East, India, Africa, South America, New Zealand, Australia, Turkey and Southern Europe.^{1,2} The disease has got different clinical presentations, depending on the organ(s) involved, and may present a clinical dilemma regarding diagnosis and treatment. Surgery for hydatid cysts has been always considered as the treatment of choice; however, other options like chemotherapy, interventional and minimally invasive procedures or combination of all, are to be put into considerations as well. In addition, selection of patients for any of these options is an important part of management. The disease might undertake a "malignant" course in the sense of high rate of recurrence, which further enforces the importance of meticulous evaluation and proper planning of treatment. In this communication, we critically reviewed the literature and present a brief summary of common clinical presentations, current methods of diagnosis, medical and surgical management, and follow-up strategy of *Echinococcus granulosus* or *Cystic Echinococcosis* (CE),

Key-words: *Echinococcus granulosus*, *Cystic echinococcosis*, *Hydatid disease*, *Pericystectomy*, *Mars up ializatio n*, *Capitonnage*, *Omentoplasty*.

Resume

Echinococose a et6 decrite par Hippocrates it y plus de deux milles ans comme un "foie remplie de liquide", suivi par un medicine arabe celebre "Al-Rahzes". Elle est endemique en Moyen Orient, à l'Indie, en Afrique, en Amerique du sud, en Nouvelle Zelande, en Australie, au Turque et en Europe du sud. La maladie possede des presentations cliniques diverses, qa depend des organes impliqu6s et elle pourrait provoquer un embarras clinique pour ce qui est du diagnostic et traitement. Depuis bien longtemps, on considerait la chirurgie ou le Kyste hydatidose comme le traitement du choix. Toutefois, d'autres solutions comme la chimiotherapie, protocole invassif minimal et interventional ou la combinaison de tout, devrait etre considers egalement.

En outre, de faire un choix des patients pour n' import quelle des options est une partie tres importante de la prise en charge. La maladie pourrait assumer une evolution "maligne" en ce sens qu'il y a un taux eleve de reaparition, ce qui davantage met en vigueur l'importance d'une evaluation meticuleuse et une organisation minutieuse de la prise en charge. Dans cette etude, nous tachons de faire un bilan critique de la littfrature et nous presentons un resume bref des presentation clinique ordinaires, des methodes

diagnostiques actuelles, la prise en charge chirurgicale et medicale, et une strategie d'une Echonococose granulosus soins post-hospitaliers ou Kyste Echinococose (KE).

Introduction

Epidemiology & life cycle

Echinococcus, a cosmopolitan zoonosis, is a tapeworm of the genus *Echinococcus* (family Taeniidae).^{3,4} It is also known as hydatid disease, echinococcosis or hydatidosis, and it is caused by infestation with larval (metacestode) or adult stages of cestodes. The adult cestode inhabits the small intestine of a carnivore (definitive host) and produces eggs containing infective oncospheres. Either cestode segments (progiottids) containing eggs or free eggs are released from the intestinal tract of the carnivore into the environment and are transmitted to humans in the course of playful and/or intimate contact with the infected animal.⁵ Following oral uptake of eggs by an intermediate host animal or human being and other "aberrant" hosts, a larval stage, the metacestode, or the oncospheres penetrate the gut wall, and are transported passively through the blood in the portal vein or lymph to the target organs, where it develops into a hydatid cyst.⁶⁻¹⁰ Once ingested, all tissues can be affected, however, the liver is infected in about 60% of cases, the lung in about 20%, and remaining organs such as kidney, brain, bone, muscles, and others in about 20%.¹¹⁻¹⁴

The two major species of medical and public health importance are *Echinococcus granulosus* and *Echinococcus multilocularis*.⁴ In this review, we would focus on *E. granulosus* or CE, being the most common form encountered in our part of the world (Africa and Asia).

Most of the cysts of CE are univesicular (i.e., unilocular) with crystal clear fluid (hydatid fluid) that has a specific gravity of 1012 and contains salts, enzymes, proteins, and toxic substances, and is antigenic.^{3,15} In some cysts, smaller daughter cysts are formed within larger mother cysts.¹⁶

Clinical manifestations of surgical importance

Infections are usually acquired during childhood, however, clinical manifestations may occur after a highly variable incubation period of several months or years, usually in adults in the third to fifth decades of life, with an equal sex distribution.^{3,5} Majority of the cysts produces no symptoms and are detected as incidental findings on routine imaging or at autopsy.³ The induction of morbidity depends on the number, size, activity, developmental status of the cyst(s), the involved organ(s), the localization of the cyst(s) within the organ, the pressure of cysts on surrounding tissues and structures, and the defense mechanisms of the infected individual.⁵ There is evidence that liver cysts grow at a slower rate than lung cysts, for example.¹⁵

Hepatic

Cysts can cause pain in the upper abdominal region, hepatomegaly, cholestasis (due to compression on the hilum), biliary cirrhosis, portal hypertension, ascites. liver abscess due to infection of the cyst. hepatic vein or inferior vena cava compression leading to Budd-Chiari syndrome.^{1,7} Cyst contents may block the ampullary orifice causing acute pancreatitis, and a variety of other related manifestations.⁹

Cysts may rupture into the peritoneal cavity, causing anaphylaxis or secondary CE, or into the biliary tree, leading to cholangitis and cholestasis, or into the pleural cavity or lung and can establish cystobronchial or biliobronchial fistula.^{5,10,22} A hydatid thrill may be elicited on a large mass

pointing to its fluid content. Rarely, the mass is calcified giving it a hard consistency, and needs to be differentiated from a primary or secondary liver tumor.

Lung

Cysts often cause no symptoms. However, a large cyst may cause pressure symptoms and lead to cough and hemoptysis. Complications arise when the cyst ruptures either into the bronchial tree or pleura. Bronchial rupture manifests with cough, chest pain and dyspnea. Rupture of cyst contents into the pleural cavity may cause allergic reactions including anaphylaxis, pleural effusion, pleural implantation and empyema. Infection of the cyst follows leakage of the cyst

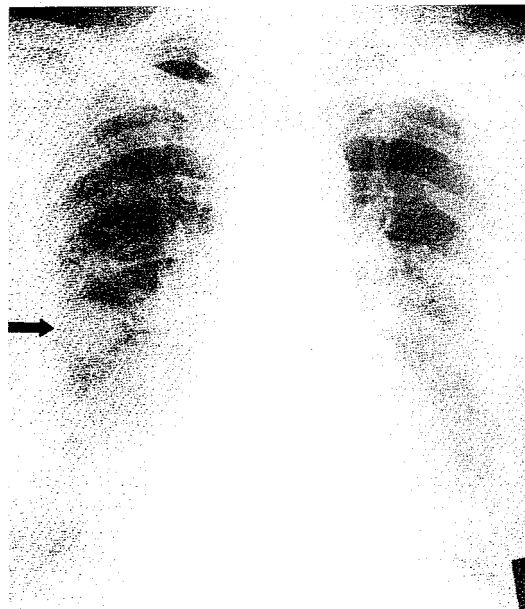


Fig. 1 Plain chest x-ray showing well-circumscribed round mass in the right lung (arrow).

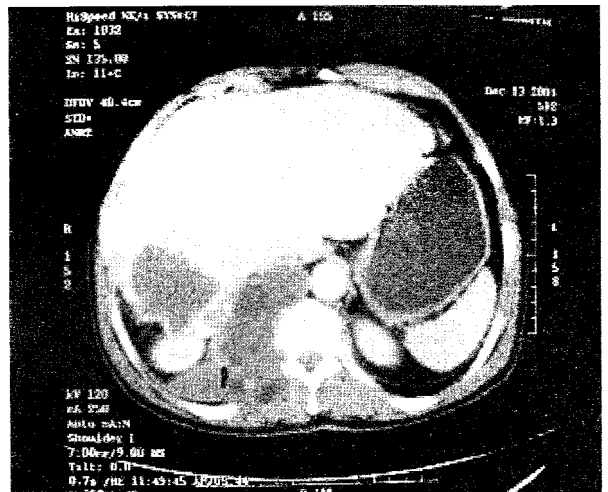


Fig. 3 CT scan of the abdomen showing calcified hepatic pericyst in the right lobe, hepatic hydatid cyst of the left lobe, and hydatid of the spine.

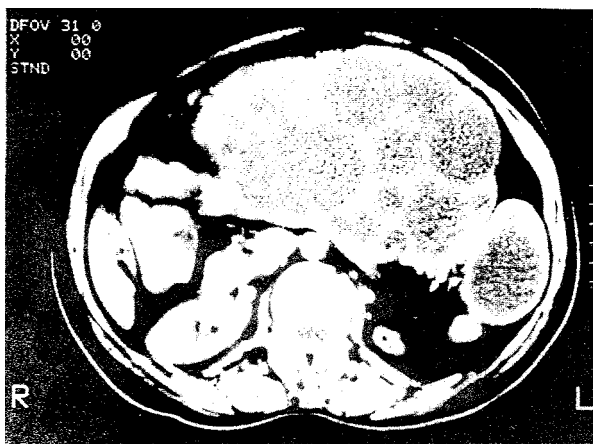


Fig. 2 CT scan of the abdomen showing multivesicular hydatid cysts of liver, pancreas and spleen.

and presents as lung abscess.^{ie, 21, 22}

Other organs

The involvement of other organs can lead to a variety of manifestations, namely soft tissue fluctuant swelling (*muscle cysts*), raised intracranial pressure and focal epilepsy (*cerebral cysts*), segmental portal hypertension (*splenic cysts*), acute pancreatitis and obstructive jaundice (*pancreatic cysts*), bone pain, swelling and pathological fractures (*bone cysts*), paraplegia (*vertebral column cyst*), conduction defects, pericardial effusion and cardiac tamponade (*cardiac cysts*), loin pain and hematuria (*kidney cysts*), unilateral exophthalmos and blindness (*orbital cyst*),²³⁻²⁵

Daughter cysts may be packed together in the mother cyst (multivesicular cyst) or float freely in the mother cyst cavity. In older cysts, the contents degenerate forming a gelatinous amber-coloured structure called the matrix. The matrix gives a pseudo-tumor appearance on imaging tools and can be confused with pus. Calcification can occur in the pericyst, mother cyst and daughter cyst. Calcification of

endocyst indicates that the cyst is nonviable. However, calcification of the pericyst is found in one-third of cysts and can occur in all stages of cyst development.²⁶

Rarely, a cyst can grow on to the skin along a sinus tract following surgery or percutaneous drainage of the cyst."

Diagnostic techniques in hydatid disease

The definitive diagnosis for most human cases of CE is based on identification of cyst structures by physical imaging techniques, predominantly ultrasonography, computed tomography, and plain X-ray examinations. This should be confirmed by detection of specific circulating antigens and/or serum antibodies by immunodiagnostic tests which play an important complementary role.^{3, 1, 19}

Imaging

There are different imaging tools that facilitate the diagnosis of CE. The site of the disease and the status of organ(s) involved and its adjacent will determine which tool(s) to be selected for optimum imaging.^{3, 26, 28, 29}

Plain X-ray

Plain radiography has a role in lung and bone cysts. Uncomplicated cyst(s) in the lung appear(s) on plain film of the chest as sharply demarcated round or oval homogenous mass of variable size (Fig. 1). A ruptured lung cyst is usually associated with air leak around the cyst; this leak is depicted on plain chest x-ray as either *air meniscus sign* (radiolucent air shadow between pericyst and intact endocyst), *double arch sign* (air delineating wall of the pericyst, the outer arch and the detached wall of the endocyst, the inner arch), or *water lily sign* (collapsed wavy endocyst membranes floating on the top of remaining cyst fluid),¹⁹ Pulmonary cysts usually do not calcify and daughter cyst formation is rare.¹⁰

Bone cysts, when expanding, usually lead to bone destruction, and a true pericyst does not develop within the bone.¹ A plain abdominal x-ray can help in diagnosing hydatidosis of abdominal and/or pelvic organs if there is cyst calcification. Calcification involving the ectocyst is typically curvilinear (egg shell calcification), however, endocyst calcification is spotty in nature and appears as speckled calcified densities.¹

Ultrasonography (US)

US is a noninvasive, readily available, sensitive, specific (90%), cost-effective imaging tool and is the diagnostic method of choice for intraabdominal CE.¹ It can detect cyst > 1cm in diameter.¹ The World Health Organization (WHO) Working Group on echinococcosis recommended a uniform classification based on ultrasonographic-morphological criteria and viability of the parasite.¹ Cysts may appear univesicular, anechoic, rounded with well-defined margins containing pure fluid, or multivesicular (daughter cysts), with a wheel-like or honeycomb appearance, and a pure fluid collection in each vesicle.^{1, 19} Cysts may have hyperechoic solid pattern (pseudotumor appearance) or may have reflective wall suggestive of calcification.¹ Ultrasound appearances of ruptured liver cyst into bile ducts include dilated bile ducts, non-shadowing echogenic structures within the ducts and

loss of continuity of the cyst wall adjacent to the bile duct indicates the site of communication and is an indication for endoscopic retrograde cholangiopancreatography (ERCP).³

Computed tomography (CT)

CT scan can detect small cysts (> 1cm in diameter), and has the potential of determining the size, the site and the detailed morphology of CE, and hence, it is considered as the method of choice for detecting lung, brain, and bone cysts and in hepatic cysts when US diagnosis is uncertain.¹ It is a useful imaging tool in the diagnosis and planning of surgical treatment of CE, especially laparoscopic approach, and in monitoring the disease following treatment.^{3, 6, 19} Depending on the organ involved, CE appears on CT as round or spherical cysts with contents near water density, univesicular or multivesicular (spherical formations within a larger 'mother cyst', with membrane detachment¹⁰ (Fig. 2). In addition, CT of cerebral cysts shows no enhancement after contrast injection and no oedema around the cyst.¹ In CE of bones, CT displays areas of osteolysis with local bone expansion and fluid formations of cyst-like appearance in soft tissue (Fig. 3). For completion of investigations, US and CT should be used in combination.⁶

Magnetic resonance imaging (MRI)

MRI gives good structural details of the hydatid cysts. It does not provide additional information for the pleuropulmonary and abdominal lesions, and is not cost-effective compared with US and CT.^{6, 19} However, MRI is superior in identifying changes in the intra- and extra-hepatic vascular system due to intrinsic contrast of vascular structures.^{6, 19}

Angiography and scintigraphy have no major advantage over the above imaging tools and are rarely employed in this setting.^{11, 21}

Serology

The rationale of serology tests is to detect specific serum antibodies (e.g. IgG1 & IgG4) and/or circulating antigens (e.g. Ag5 & AgB) by a variety of immunodiagnostic methods.^{11, 41} An optimum test should be specific with high sensitivity. Detection of circulating *E. granulosus* antigens in sera is less sensitive than antibody detection, which remains the method of choice.¹ The enzyme-linked immunosorbent assay (ELISA), the indirect immunofluorescence antibody test, immunoelectrophoresis (IEP), and immunoblotting (I13) are sensitive and specific tests.¹ The ELISA which employs hydatid fluid antigen for detection of echinococcal antibodies (IgG) in the serum is the most widely used.¹ This test has a sensitivity of 80% - 100% and specificity of 88% - 96% in hepatic cysts.¹ However, the sensitivity of this test is around 50% - 56% in pulmonary cysts and 25% - 56% in cysts involving other organs.¹ False-positive test can occur in normal persons from endemic areas and in those with other parasitic infections.¹ Positive test results need confirmation by the arc-5 immunoelectrophoretic (IEP) test, which detects antibodies against immunodominant and specific antigen (antigen 5) of the cestode. This test does not cross-react

with non-cestode parasites.' Furthermore, it should be remembered that approximately 10 to 20% of patients with hepatic cysts and about 40% with pulmonary cysts do not produce detectable specific serum antibodies (IgG) and therefore give false-negative results."¹⁹ Cysts in the brain, bone, or eye and calcified cysts often induce no or low antibody responses." In routine laboratory practice, usually at least two different tests are used to get the most reliable results.⁵

The results of serological tests depend on many factors, such as age of the patient (children may have a low antibody response),⁶ organ(s) involved and number of cysts, and the status of the immune system." Insensitive and nonspecific tests, including the Cassoni intradermal test, the complement-fixation test, the indirect haemagglutination test, and the latex-agglutination test, have been replaced by the above-mentioned tests.

Other diagnostic tests

Ultrasonography-guided fine-needle puncture has been used in recent years as a diagnostic procedure in doubtful cases of CE, i.e., when imaging and serological tests do not permit discrimination between hydatid cyst and neoplasm, abscess, simple cysts or other conditions."¹⁹ It carries the risk of anaphylaxis and spillage of cyst contents with secondary echinococcosis.³ Aspirated cyst fluid can be examined for protoscoleces, rostellar hooks, and *Echinococcus* antigens or DNA.' To prevent secondary echinococcosis when a hydatid cyst is punctured, chemotherapy with albendazole is recommended for 4 days before the procedure.' Chemotherapy should be continued for at least 1 month after puncturing a lesion that was diagnosed as an *E. granulosus* cyst, even after its immediate surgical removal."

Treatment options in CE

The treatment of CE should be decided and started once the disease is diagnosed. This will prevent complications such as secondary infection, rupture of the cyst into adjacent structures, rupture with dissemination of the disease, anaphylactic reaction, pressure on contiguous organs, and penetration into other organs.'

Small hydatid cysts (<4cm) located deep in the parenchyma (e.g. of liver), if non-complicated, can be managed conservatively, because they usually cause no symptoms, grow slowly, and are difficult to approach.' Treatment of CE ranges from surgical intervention (conventional or laparoscopic approach) to puncture- aspiration- injection-reaspiration (PAIR), medical therapy, and 'wait and observe' approach.^{1,6,1,29}

Surgery

Surgery, using various technical approaches, has the potential to remove the entire cysts and lead to complete cure.^{3, 5,18,19} In simple, accessible cyst, surgery can be successfully performed in up to 90% of patients.

Aims of surgery'

- * Entire elimination of the viable parasite (endocyst)

- * Prevention of intraoperative contamination (spillage)
- * Inactivating infectious material (scolices and germinative membrane)
- Managing the residual cavity
- Saving healthy tissue

Indications for surgery

Surgery is indicated for non-complicated cysts with a peripheral location in patients who are in good general condition.' The WHO working group on Echinococcosis has suggested specific indications for hydatid surgery:"

- Large liver cysts with multiple daughter cysts
- Single superficially situated liver cysts that may rupture spontaneously or as a result of trauma
- Infected cysts
- Cysts communicating with the biliary tree and/or exerting pressure on adjacent vital organs
- Cysts in the lung, brain, kidney, bones, and other organs.

Contraindications to surgery^{3,5,6, 19}

- Patients refusing surgery
- Patients at the extremes of age
- Patients with concomitant severe comorbidities
- Pregnant women
- Patients with multiple cysts in several organs or those with cysts which are difficult to access
- Dead cysts (either partially or totally calcified)
- Very small cysts, and in some highly endemic regions with long waiting lists and lack of adequate medical structures or experienced staff, or if facilities for advanced surgery are inadequate.

Surgical treatment^{1,19 20}

The surgical treatment of hydatid disease can either be *radical* or *conservative*. The *radical* procedures include pericystectomy, hepatic resection, and lobectomy as in cases of hepatic or lung CE respectively. It means that the intact cyst(s) with a fairly wide safely margin are resected. A meta-analysis has shown the best results regarding mortality, morbidity and recurrent rates to be (1.2%), (11.7%) and (2%) respectively for resective operations.' Although radical procedures are associated with a lower risk of recurrence, they are associated with high intraoperative risk for a benign disease. *Conservative* surgical treatment, on the other hand, is safer, easier to perform, but associated with more prevalent morbidity. The procedure involves deroofting of the cyst, removing the parasite and keeping the pericyst (cystectomy/endocystectomy) with various procedures for the management of the residual cavity. The meta-analysis presented revealed a mortality of 2%, morbidity of 23%, and recurrence rate of 10.4% for these operations.'

Despite alternative procedures, surgery remains the treatment of choice for CE. The risks of surgical treatments include secondary echinococcosis due to spillage of viable parasite during surgery or incomplete removal of cyst (prevalence ranges between 2% and 25%), anaphylactic reactions and those associated with surgical intervention in general.^{1, 11} The postoperative mortality is about 2% (0.5% - 4.0%), depending on the number of surgeries done for CE

and the available facilities.^{3,11} Operative mortality for recurrent disease increases with the number of operations; Saimot^o reported a series with mortality rates of 0.9 - 3.6% for the first operation, 6% for the second, and 20% for the third.

In a prospective comparative study, Tasev et al.³⁰ concluded that radical surgical procedures were associated with lower postoperative morbidity and mortality rates and a shorter postoperative hospital stay compared with conservative procedures. However, these procedures were performed more frequently for hydatid cysts located in the left hepatic lobe. Schmidt-Matthiesen et al.¹² reported a comparative retrospective study and concluded that conservative procedures were preferable to pericystectomy which had a higher morbidity. Unfortunately, there is no randomized trial comparing radical versus conservative treatment and therefore, it would be very difficult to conclude which treatment is better before we perform a prospective, randomized trials to compare both.

Procedures

The surgical procedures start usually by confirming the presence of the cyst(s) in a surgically accessible position, and exploring the rest of the area for missed cyst(s). This is followed by packing off the adjacent area next to the cyst using disinfectant-soaked towels to reduce the risk of contamination and secondary echinococcosis.⁶ Different disinfectants have been used and the recommended ones are mentioned later in this review. In some settings, the use of a cone as described by Aarons and Kune, and Saidi and Nazarian, can prevent spillage of the cyst content and simplify the disinfection of the cyst cavity.¹ The cyst is opened through the cone, the parasite sucked off entirely, and the remaining cavity disinfected. Aarons and Kune use negative pressure to fix the cone to the pericyst, which is simpler than using a cryogenic device.¹

The use of scolical agents has been regarded by WHO as questionable, since there is no ideal agent that is both effective and safe.¹² The substances whose use have been reported include polyvinylpyrrolidone-iodine (PVP) 10%, a mixture of cetrimide 1.5% and chlorhexidine 0.15% (Savlon 10%), ethylalcohol 95%, hydrogen peroxide 3%, silver nitrate 0.5%, as well as dilutions of these substances.⁶ WHO considers Ethanol (70 - 95%), hypertonic saline (15 - 20%), and cetrimide solution (0.5%) to be substances with a relatively low risk.¹² For optimal efficacy, the substances should be left in the cyst for at least 15min.¹⁹ More experimental studies and clinical observations are urgently needed to evaluate the efficacy and safety of protoscolicides.¹⁹

The reported adverse effects of scolical solutions include sclerosing cholangitis (caustic damage to the epithelium of communicating bile ducts), low efficacy, air embolism, anaphylactic shock, PVP storage disease, renal shutdown, sterile peritonitis, sclerosing serositis, chemical peritonitis, metabolic acidosis, and methaemoglobinaemia.⁶ Supportive measures comprise the use of scolical agents and postoperative benzimidazole administration. However, a critical review of the literature to date reveals a lack of scientific confirmation of established treatment modalities

and procedures.¹

Buttenschoen et al.¹ elaborated on the numerous terms used in the literature for the surgical procedures employed in hydatid surgery. These include: Marsupialization; simple external tube drainage; simple resection of the prominent part of the cyst; cystectomy (partial or total); cystopericystectomy (open and closed, partial and total); endocystectomy with m.arsupialization or omentoplasty; capitonnage; Whipple procedure; cystojejunostomy. There are also combinations of various procedures with or without additional use of scolical agents. They described the different procedures as follows:

Pericystectomy

The cyst and a more or less thick coat of healthy parenchyma are resected. In the open-cyst method, the parasite foci are sterilized with scolical agents, the contents of the cyst are evacuated, and the pericyst is removed. The closed-cyst method entails *en-bloc* resection of the parasite, including the pericyst without cutting into the pericyst.⁶

Partial/subtotal (cysto-) pericystectomy

Removal of the endocyst and partially/subtotally the pericyst.^o

Marsupialization

Drainage of the residual cyst cavity (which usually remains open) externally, leaving the pericyst intact. The cyst edges are sewn to the peritoneum/abdominal wall. This procedure has been abandoned because the associated morbidity is unacceptable.¹

Capitonnage and introflexion

The size of the cyst cavity is reduced by coapting the cyst walls to each other or enrolling the edges of the parenchyma into the cavity. Capitonnage is not possible if the volume of the cyst is large, or if the walls are calcified and rigid. The risk during capitonnage includes possible injuries to the hepatic veins and bile ducts which run close to the cyst wall in liver cysts.¹

Omentoplasty

The cavity is filled by a pediculated part of the greater omentum. The reported advantages include resorption of fluid, reduced risk of infection and bile fistulation, acceleration of wound healing, and hemostatic properties. Prospective studies have shown omentoplasty to be associated with significantly fewer postoperative complications (6%) than external drainage (23%).⁶ A multicenter, prospective, randomized trial found the rate of deep abdominal complications after surgery for hydatid disease of the liver (partial and total pericystectomy) to be significantly reduced by omentoplasty (10% vs. 23%).⁶

Liver resection

Hemihepatectomy and hepatic lobectomy are indicated based on the anatomical criteria and parasite location. These procedures are thus recommended if the parasite occupies particular anatomical regions almost entirely.¹

Management of the cyst cavity

After pericystectomy and conservative procedures., there are several methods for dealing with the remnant cavity in the liver.

- (a) The cavity can remain open with or without drainage, leaving the volume of the cavity as it is.' Oversewing the cyst edges prevents bleeding.
- (b) Small, noncalcified, or infected cysts can be filled up with normal saline and closed by a suture.'
- (c) Marsupialization'
- (d) Capitonage and introflexion'
- (e) Omentoplasty'

Medical treatment (Chemotherapy)

Benzimidazoles (Imidazoles): *Mebendazole* (Vermox; 500mg tablets, Janssen Cilage, Belgium) and *Albendazole* (Eskazol, Zentel; 400 mg tablets and 4% suspension, Smith Kline and French, England) are the drugs of choice, although their real effects (parasitostatic or parasitocidal) have not yet been fully determined.' *Praziquantel* (Biltricide; E. Merck/Bayer AG, Germany), an isoquinolone derivative has a marked effect on protoscolex viability in *vitro*,³² Results for over 2,000 well-controlled cases treated with benzimidazoles and evaluated for up to 12 months have shown that cysts disappeared in 10 to 30% of the patients (cure), there was objective evidence of response in 50 to 70% (degeneration or size reduction of cysts), and 20 to 30% did not exhibit morphological changes of the cysts.'-¹⁹ Others reported cyst disappearance of 30%, partial response in another 30% and no response in 40%.³ Relapses after chemotherapy have been observed in 14 to 25% of patients, but are usually sensitive to retreatment.¹⁹

Aims of medical treatment^{1,19}

- Preoperative treatment with benzimidazoles softens the cysts, thereby reducing intracystic pressure and simplifying their removal.
- To reduce the risk of secondary echinococcosis and recurrence.

Indications for medical treatment

- Patients who are high risks for surgery.',⁵
- Patients with inoperable CE (intraparenchymal, e.g. liver, spine and pelvis)."
- Patients with multiple cysts in two or more organs.¹⁹
- Small cysts (<4cm diameter), and cysts with thin walls and in younger patients.'
- Prevention of secondary echinococcosis after spillage during surgery.',¹⁹
- Partial cyst removal or biliary rupture.'
- As a concomitant therapy with percutaneous drainage (PAIR) or surgery.'

Contraindications to medical treatment¹⁹

- Large cysts with a risk of rupture (superficially situated, infected cysts).
- Inactive or calcified cysts
- Patients with chronic liver diseases and bone marrow depression should not undergo benzimidazoles treatment.

Pregnancy

Doses, duration and regimens of medical treatment

Albendazole: According to WHO recommendations, it is given in oral daily doses of 10 to 15mg/kg of body weight (bw) in two divided doses postprandially (800mg/day in two single doses of 400mg each) for 3 to 6months.¹⁹

Mebendazole: The usual dose of mebendazole is 40 to 50mg/kg bw per day in three divided doses orally for a least 3 to 6 months.¹⁹

Drug dosing with a fat-rich meal improves absorption of benzimidazoles.¹⁹ In a comparative study with 448 patients, Franchi et al.⁵ assessed the efficacy of mebendazole and albendazole treatment (3 to 6 months) and found degenerative changes in 82% of the cysts in the albendazole group and in 56% in the mebendazole group (p < 0.001). Mebendazole is poorly absorbed compared to Albendazole.³ Three available randomized clinical trials (RCTs) showed that Albendazole had a better effect on hydatid cysts than placebo or Mebendazole.^{20, 33}

Praziquantel: The WHO has proposed Praziquantel at a dose of 40mg/kgbw once a week concomitantly with benzimidazoles.¹⁹ It has also been shown that a combined treatment of albendazole (10 mg/kg/day) and praziquantel (25 mg/kg/day) given for one month prior to surgery results in more nonviable protoscolexes than albendazole alone." One prospective controlled trial compared albendazole and praziquantel, versus albendazole alone and concluded that the combined treatment was more effective than albendazole alone.³⁴ However, complete disappearance of all cysts did not occur in any of the studies reported. Further studies on this issue are needed.

The required duration of chemotherapy preoperatively has not been definitively determined, but should not be less than 3 months.' Postoperatively, the WHO recommends chemotherapy for at least imonth (Albendazole) or 3 months (Mebendazole) in cases in which spillage of protoscolexes may have occurred.' There are no published data on the added benefit of postoperative Albendazole in patients undergoing a complete surgical cure.' There is, as yet, no formal consensus regarding the efficacy and safety of some of the methods and this requires further evaluation before we can establish comprehensive guidelines for the medical treatment of hydatidosis.

Many studies support the combined treatment with praziquantel and albendazole and reported their scolocidal on CE^{3,1,31} Cyclic treatment (three 1-month courses with intervals of 14 days) has been widely used,' Albendazole at a dose of 10 to 15mg/kg of body weight in two divided doses postprandially, and Praziquantel at a doze of 40mg/kg once a week.' Recent data show that uninterrupted drug therapy for 3 - 6 months has better efficacy with no increase in adverse effects.',¹⁹

Side effects of chemotherapy

These are generally mild and rarely treatment-limiting.'
§ Benzimidazoles are hepatotoxic (transient rise in aminotransferases), can cause pancytopenia and

agranulocytosis, proteinuria, transient alopecia, gastrointestinal disturbances, and are potentially embryotoxic and teratogenic.^{3,6,19} In all cases, these events disappear once treatment with albendazole is interrupted.⁶ Common adverse effects of Praziquantel include drowsiness, dizziness, malaise, anorexia as well as gastrointestinal upsets.³⁶ The rate of side effects of albendazole is increased when Praziquantel is given simultaneously."

Laparoscopic surgery

Although the laparoscopic approach to the treatment of hydatidosis is safe, further studies are necessary to evaluate the recurrence rate.' The results of a number of trials have been published in the literature, although none of them was comparative or randomized. Khoury et al.³⁷ reported 108 patients with hydatid cyst of the liver operated upon laparoscopically. The mean operating time was 80 minutes (range 40 - 180 minutes), and there was no mortality. Complications occurred in 11% of the patients, and disease recurrence was recorded in 3.6% with a mean follow-up of 30 months (range 4 - 54 months). Khoury et al.³⁷ and others^{11,39} concluded that the laparoscopic approach for uncomplicated hydatid cysts of the liver was a safe, effective option with favourable long-term results.

Compared with open surgery, laparoscopic approach has got the advantages of a shorter hospital stay, lower incidence of wound infection, less invasiveness and less postoperative pain.^{1,20} On the other hand, limited area of manipulation, increased risk of spillage of the cyst content and difficulty in controlling it, the difficulty of aspirating the thick, degenerated cyst contents when viscous, and the difficulty in approaching deeply-seated lesions have resulted in limited popularity of such a procedure.^{1,20}

Laparoscopic procedures include total excision, or deroofting, evacuation, and obliteration of the cyst cavity.' The cyst cavity can be examined in more detail. Proper selection of patients for the laparoscopic approach is important. Centrally located cysts carry a high risk of bleeding and should be treated by conventional open methods.⁶

Although, the laparoscopic approach appears more cost-effective, comparative, prospective, randomized controlled studies comparing laparoscopic treatment with conventional open surgery or percutaneous drainage, with special emphasis on recurrence rates, need to be performed and evaluated before definite conclusions can be drawn.'²⁰

Puncture-aspiration-injection-reaspiration (PAIR)

PAIR was introduced in the mid-1980s⁵ The procedure is minimally invasive, cost-effective, involves reduced hospital stay and has less morbidity and mortality than surgery.'⁵ It includes the following steps (i) percutaneous puncture of the cyst under ultrasonographic guidance, (ii) aspiration of a substantial portion (for example, 10 to 15ml) of the cyst fluid, (iii) injection of a parasitocidal solution (95% ethanol; approximately an equivalent of one third of the amount aspirated, or 15% hypertonic NaCl solution), and (iv) reaspiration of the fluid content after 5min when ethanol is used, or 15 - 20 min if hypertonic NaCl solution is used.⁵

A guideline for the performance of PAIR has recently

been published.⁵ PAIR is the treatment of choice in patients with hepatic hydatid cysts who either refuse surgery or have significant co-morbid diseases.' The procedure is highly effective in intact univesicular and multivesicular cysts with few large daughter cysts, cysts with diameters of over 5cms and multiple cysts in different liver segments.³ Cysts that relapse after surgery or failed to regress following chemotherapy are amenable to percutaneous drainage.', s Recommendations have been made that PAIR should be accompanied by chemotherapeutic coverage to minimize the potential risk of secondary echinococcosis^{5,19} In such situations, albendazole is administered in daily oral doses of 10mg/kg of body weight 4 days before PAIR and at least for one month after the intervention, and for 3 months if Mebendazole was used.'¹¹ Compared with surgery, PAIR plus chemotherapy is associated with more clinical and parasitological efficacy, lower rates of morbidity, mortality, and disease recurrence and shorter hospital stay.⁷⁰

The main contraindications for PAIR are: infected cysts, superficial or pedunculated cysts, those communicating with the biliary tree, cysts in a risky or inaccessible location in the liver, cysts with honeycomb appearance (multiple, small daughter cysts), cysts with dominant solid component, cysts free in the abdominal cavity, and cysts in the lungs, heart, brain or spine.^{3,5,19} Great care must be taken to detect cysts with biliary communications in order to prevent an influx of parasitocidal solution into the biliary tree and the risk of chemical (sclerosing) cholangitis. It is therefore, a basic requirement to examine aspirates from liver cysts for traces of bilirubin. Furthermore, ERCP is used to rule out cysto-biliary communications.' If bilirubin is present in the cyst fluid, the PAIR procedure must be discontinued. There are indications that PAIR has several detrimental effects to the parasite, including (partial) detachment of endocyst membranes from the pericyst and/or damage of the germinal layer and protoscolexes by the parasitocidal solution.

The procedure is associated with possible complications of liver puncture (bleeding, bile peritonitis), anaphylaxis, allergic reactions and biliary communications.' Long-term follow-up has shown that secondary echinococcosis does not occur following percutaneous drainage."

Percutaneous thermal ablation (PTA)

Alternative methods comprise percutaneous evacuation (PEVAC) and radiofrequency thermal ablation.⁶ This treatment involves percutaneous thermal ablation (PTA) of the germinal layer in the cyst by using a radiofrequency ablation device. Brunetti and Filice⁴⁰ have reported the use of PTA for treating two patients with hepatic cysts. PTA has the advantage that injection of parasitocidal substances into the cyst is unnecessary. However, more experience with this technique is needed.

Follow-up after treatment

Patients with CE need to be carefully monitored after surgery or drug treatment to ensure that they remain free from infection and disease. Both imaging and serological evaluations are valuable methods of monitoring patients after treatment.^{4,19} Ultrasound and/or CT scans are the methods

of choice for imaging. For serological evaluation, detection of the IgG4 antibody subclass is a good marker for the follow-up of hydatidosis.⁴ While detection of IgG4 becomes negative soon after successful surgery, it maintains high IgG4 titers in ELISA inpatients with relapsing disease.' Specific IgE and IgM ELISAs are also useful in this respect.' In patients in whom cysts have been removed successfully, peripheral blood mononuclear cells (PBMC) isolated from CE patients can be driven in *vitro* by hydatid cyst fluid (HCF) antigens to produce large amount of cytokines⁴ Interleukin-4 (IL-4) detection may be useful in the follow up of patients with CE. Furthermore, this can be combined with reverse transcriptase. PCR to determine the mRNA expression of cytokines in PBMC to complement the biological assays in the follow-up. Detection of circulating antigens is also relevant as a method of post-surgical follow-up of patients and for monitoring the growth dynamics and/or the activity of cysts.' Elongation factor - 1(3/6 (EF- 1(3/8), a parasite protein present both in protoscolices (PSC) and hydatid fluid, is a sensitive marker of infection. The higher percentage of humoral immune responses to EF -1(3/8 observed in CE patients with calcified cysts than in patients with active cysts suggests that the protein is released into the hydatid fluid after the degeneration of PSC and indicates its possible use in immunosurveillance of CE.' Moreover, EF-1(3/8 may play a key role in the allergic disorders (urticaria, itching, anaphylactic shock) that often complicate the course of CE.⁴ The titers start falling at 3 months and become negative in a period of 12 - 24 months³

It is also important to monitor the medical treatment for possible adverse reactions of benzimidazoles. Leukocyte counts should be checked at 2-week intervals during the first 3 months to detect reversible leukopenia.¹⁹ Also, serum drug concentrations at 2 and 4 weeks of chemotherapy, if facilities are available, are a valuable way of monitoring drug treatment.¹⁹

Conclusion

This review would allow us to arrive at the following conclusions regarding clinical characteristics, diagnosis and treatment of CE:

1. Cystic echinococcosis should be suspected in patients with cystic lesions, particularly those living or coming from endemic areas.
2. Ultrasound and/or computed tomography are the best tools for imaging hydatid cysts, and the diagnosis should be confirmed by the detection of either IgG echinococcal antibodies using ELISA, or specific antigen (antigen 5) using the arc-5 immunoelectrophoretic (IEP) test.
3. Surgical treatment should be considered for large (more than 4 cms), accessible and infected cyst. Omentoplasty is an efficient option for residual cavity in open surgery for abdominal cysts especially hepatic ones.
4. Chemotherapy alone is useful in small cysts or inoperable patients, and in combination with surgical intervention.
5. Combined Albendazole and Praziquantel treatment has a significant support in the literature.
6. The laparoscopic approach is safe. However, further studies are necessary to evaluate the recurrence rate.
7. Percutaneous drainage associated with albendazole

therapy is safe and efficient in selected patients.

References

1. Abu-Eshy S, Elamin Ali M. Hydatid cyst associated with pregnancy: A case report and review of the literature. *Ann Saudi Med* 1999; 19: 130 - 131.
2. Jastaniah S, Malatani T S, Abu-Eshy S, Al Shehry M, Hamdi J, Al Naami M, Biomy A, Ghatani S. S. Hydatid cyst disease (Echinococcus granulosus): Experience at Asir central hospital, Saudi J Gastroenterol 1997; 3: 140 - 143.
3. Khuroo M S. Hydatid disease: current status and recent advances. *Ann Saudi Med* 2002; 22: 56 - 64.
4. Zhang W, Li J, McManus D P. *Clinical Microbiology Reviews: Concepts in Immunology and diagnosis of hydatid disease* 2003; 16: 18 - 36.
5. Eckert J, Deplaze P. *Clinical Microbiology Reviews: Biological, epidemiological, and clinical aspects of Echinococcosis, a Zoonosis of increasing concern* 2004; 17: 107 - 135.
6. Buttenschoen K, Carli Buttenschoen D. Echinococcus granulosus infection: the challenge of surgical treatment. *Langenbecks Arch Surg* 2003; 388: 218 - 230.
7. Abbas A K, Murphy K M, Sher A. Functional diversity of helper T lymphocytes. *Nature* 1996; 383: 787 - 793.
8. Aceti A, Pennica A, Teggi A, Fondacaro L M, Cafarro M, Leri O, Tacchi G, De Rosa F, Sebastani A. IgG subclasses in human hydatid disease: prominence of the IgG4 response. *Int Arch Allergy Immunol* 1993; 102: 347 - 351.
9. Ali-Khan Z. Cellular changes in the lymphoreticular tissues of 0571 L/J mice infected with *Echinococcus multilocularis* cysts. *Immunology* 1978; 34: 831 - 839.
10. Ali-Khan Z. *Echinococcus multilocularis*: cell-mediated immune response in early and chronic alveolar marine hydatidosis. *Exp. Parasitol* 1978; 46: 157 - 165.
11. Ammann R, Eckert J. Clinical diagnosis and treatment of echinococcosis in humans. In: Thompson R C A, Lymbery A J (eds) *Echinococcus and hydatid disease*. C A B International, Wallingford, 1995; 411 - 463.
12. Kehila M, Ammar N, Hattab C, Letaief R, Khabthani H, Hamida R B, Khalfallah A, Said R, Jerbi A, Gharbi S. Etude statistique des localizations hydatiques. A propos de 644 cas, 1980 - 1986. *Tunis Med.* 1988; 66: 587 - 591.
13. Wilson J F, Diddams A C, Rausch R L. Cystic hydatid disease in Alaska. A review of 101 autochthonous cases of Echinococcus granulosus infection. *Am Rev Respir Dis* 1968; 98: 1 - 15.
14. Abu-Eshy S A. Some rare presentations of hydatid cyst (*Echinococcus granulosus*). *J R Coll Surg Edinb* 1998; 43: 347 -352.
15. Larrieu E J, Frider B. Human cystic echinococcosis: contributions to the natural history of the disease. *Ann Trop Med Parasitol* 2001; 95: 679 - 687.
16. Thomas P S, Owen E R, Larson H E. Hydatid disease and cholestasis. *Br J Clin Pract* 1990; 44: 336 - 337.
17. Zanzi I, Sapunar J, Croizet V, Bancalari G. Budd-Chiari syn-

- drome due to hepatic hydatidosis. *Boletin Chileno de Parasitologica* 1967; 22: 113 - 8.
18. Ammann R W, Eckert J. Cestodes: *Echinococcus*. *Gastroenterol Clin North Am* 1996; 25: 655 - 689.
 19. Pawlowski Z, Eckert S J, Vuitton D A, Ammann R W, Kern P, Craig P S, Dar F K, De Rosa F, Filice C, Gottstein B, Grimm F, Macpherson C N L, Sato N, Todorov T, Uchino J, von Sinner W, Wen H. 2001. Echinococcosis in humans: clinical aspects, diagnosis and treatment. p. 20 - 66. *In* J Eckert, M A Gemmell, F - X Meslin and Z S Pawlowski (ed.), WHO/OIE manual on echinococcus in humans and animals: a public health problem of global concern, World Organisation for Animal Health, Paris. France.
 20. Dziri C, Haouet K, Fingerhut A. Treatment of Hydatid Cyst of the Liver: Where is the evidence? *World J Surg* 2004; 28: 731 -736.
 21. Milicevic M. Hydatid disease. In: Blumgart LH, editor: *Surgery of the liver and biliary tract*. 2nd edition. Vol. 2 Edinburgh: Churchill Livingstone, 1994; 1121 - 50.
 22. Alshehri M Y. Gastropleural fistula associated with hepatic hydatid cyst. Report of a case and review of literature. *Emirates Med J* 1994; 12: 154 - 156.
 23. Merkle E M, Schulte M, Vogel J, Tomczak R, Rieber A, Kern P, Goerich J, Brambs H J. Musculoskeletal involvement in cystic echinococcosis: report- of eight cases and review of the literature. *Am J Roentgenol* 1997; 168: 1531 - 1534.
 24. Yatto G N, Khuroo M S, Zargar S A, Bhat F A, Soft B A. Percutaneous drainage of the hydatid pancreatic cyst with obstructive jaundice. *J Gastroenterol & Hepatology* 1999; 14: 931-934.
 25. Hageman G, Gottstein B, Witte O W. Isolated Echinococcus granulosis hydatid cyst in the CNS with severe reaction to treatment. *Neurology* 1999; 52: 1100 - 1101.
 26. Lewall D B. Hydatid disease: biology, imaging and classification. *Clin Radiol* 1998; 53: 863 - 874.
 27. Khuroo M S. Percutaneous drainage of hydatid cysts. *N Engl J Med* 1998; 392: 391 - 393.
 28. Zargar S A, Khuroo M S, Khan B A, Dar M Y, Alai M S, Koulex P. Intrabiliary rupture of hydatid cyst: sonographic and cholangiographic appearances. *Gastrointest Radiol* 1992; 17: 41 - 45.
 29. Von Sinner W. Advanced medical imaging and treatment of human cystic echinococcosis. *Semin Roentgenol* 1997; 32: 276-290,
 30. Tasev V, Dimitrova V, Draganov K et al. Hepatic echinococcosis: radical or conservative surgical treatment. *Khirurgiia (Sofia)* 2002; 58: 10 - 13.
 31. Schmidt - Matthiesen A, Schott O, Enche A. Surgery and long term follow-up of hepatic echinococcosis outside endemic regions. *Z Gastroenterol* 2002; 40: 51 - 57.
 32. Morris D L, Richard K S. Hydatid disease: Current medical and surgical management. In: Morris D L, Richards K S. editors, *Chemotherapy: laboratory and field studies*. 1st edition, Oxford: Butterworth-Heinemann Ltd; 1992; 79.
 33. Gil-Granede L A, Rodriguez-Caabeiro F, Prieto J G et al. Randomized controlled trial of efficacy of albendazole in intra-abdominal hydatid disease. *Lancet* 1993; 342: 1269 - 1272.
 34. Mohammed A E, Yasawy M I, Al Karawi M A. Combined albendazole and praziquantel versus albendazole alone in the treatment of hydatid disease. *Hepatogastroenterol* 1998; 45: 1690- 1694.
 35. Mohammed A E, Yasaway M I, Al Karar M A. Combined Albendazole + Praziquantel vs Albendazole alone in the Treatment of Hydatid Disease. *Saudi Med J* 1995; 16: 72.
 36. Mycek M J, Harvey R A, Champe P C. Pharmacology. In: Mycek M J, Harvey R A, Champe P C. editors. *Anthelmintic drugs*. 2nd edition. Philadelphia: Lippincott Williams & Wilkins: 2000: 362.
 37. Khoury G, Abiad F, Geagea T et al. Laparoscopic treatment of hydatid cysts of the liver and spleen. *Surg Endosc* 2000; 14: 243-245.
 38. Kathkouda N, Hurwitz M, Gugenheim J et al. Laparoscopic management of benign solid and cystic lesions of the liver. *Ann Surg* 1999; 229: 460 - 466.
 39. Descottes B, Glineur D, Lahachi F et al. Laparoscopic liver resection of benign liver tumors. *Surg. Endosc* 2003; 17: 23 - 30.
 40. Brunetti E, Filice C. Radiofrequency thermal ablation of echinococcal liver cysts. *Lancet* 2001; 358: 1464.